



CENTRE FOR DISEASE CONTROL  
NORTHERN TERRITORY

# Guidelines for the Control of Gonococcal Conjunctivitis in the Northern Territory

November 2005

*Guidelines for the Control of Gonococcal Conjunctivitis in the Northern Territory*

Prepared by the Centre for Disease Control.

1<sup>st</sup> Edition August 1997  
2<sup>nd</sup> Edition January 2003  
3<sup>rd</sup> Edition November 2005

**Further copies available from**

Centre for Disease Control  
Department of Health and Community Services  
PO Box 40596  
Casuarina NT 0811

OR

<http://www.nt.gov.au/health/cdc/protocols.shtml>

**Comments are welcome and should be directed to the Project/  
Research Officer at the above address.**

|                                                                             |                 |
|-----------------------------------------------------------------------------|-----------------|
| <b>Background .....</b>                                                     | <b>4</b>        |
| <b>Clinical Picture .....</b>                                               | <b>4</b>        |
| <b>Mode of Transmission .....</b>                                           | <b>4</b>        |
| <b>Incubation .....</b>                                                     | <b>5</b>        |
| <b>Period of Communicability.....</b>                                       | <b>5</b>        |
| <b>Case Definition .....</b>                                                | <b>5</b>        |
| <i>Clinical features.....</i>                                               | <i>5</i>        |
| <i>Case definition.....</i>                                                 | <i>5</i>        |
| <i>Epidemic definition .....</i>                                            | <i>5</i>        |
| <b>Pathology tests.....</b>                                                 | <b>6</b>        |
| <b>Management of Cases .....</b>                                            | <b>6</b>        |
| <b><i>For all suspected cases.....</i></b>                                  | <b><i>6</i></b> |
| <b><i>Management of Cases in babies.....</i></b>                            | <b><i>6</i></b> |
| <b><i>Management of sporadic cases in older children or adults.....</i></b> | <b><i>7</i></b> |
| <b><i>Management of an Epidemic situation.....</i></b>                      | <b><i>7</i></b> |
| <b>General measures and advice for all cases and contacts.....</b>          | <b>9</b>        |
| <b>Bibliography .....</b>                                                   | <b>10</b>       |
| <b>Flow chart—Management of gonococcal conjunctivitis .....</b>             | <b>11</b>       |

## Background

Gonococcal conjunctivitis is a highly contagious eye infection caused by *Neisseria gonorrhoeae*. It is a notifiable disease. It can arise in several different situations. Babies of women with genital gonorrhoea can be infected at birth (neonatal gonococcal ophthalmia). Small numbers of sporadic cases in children or adults occur every year in the Northern Territory (NT) as a result of auto-inoculation in a person with genital gonorrhoea. More rarely, epidemics can occur within a remote community or over several communities and may involve dozens or even hundreds of cases. This has occurred in central Australia 4 times in the past 25 years. A smaller epidemic has been observed in the Top End as well.

Any case indicates the possibility of an epidemic occurring. Urgent notification is required and investigation of the circumstances with a public health response is essential. Sporadic cases in children raise the possibility of sexual abuse.

## Clinical Picture

Gonococcal conjunctivitis is usually a localised, fairly severe infection of the conjunctiva with intense inflammation and copious purulent discharge with or without periorbital oedema. Corneal ulceration, perforation and blindness can occur if treatment is not given promptly. It is also possible for the infection to be quite mild and endure for several weeks or months.

Neonatal infection is a more serious clinical situation than that usually seen in older children and adults because of its greater potential to cause corneal perforation.

## Mode of Transmission

*Neonatal infection* (gonococcal ophthalmia neonatorum) occurs during passage of the infant through the birth canal if the mother is infected with genital *Neisseria gonorrhoeae*.

*Sporadic cases* occur in older children and adults where the source is usually someone with a genital infection. This may occur where:

- A person who has genital gonorrhoea who (usually) accidentally infects his or her eyes by touching them with fingers or fomites (eg clothes, towels) contaminated with their genital secretions.
- A person becomes infected by contact with the contaminated fingers or fomites of another person who has genital gonorrhoea.

*Epidemics* can arise from a person with gonococcal conjunctivitis transmitting infection by direct, non-intimate interpersonal contact, contact with infected fomites (eg clothes, towels) or by transmission by flies. Such epidemics usually occur in remote communities and have been associated with increased fly numbers following heavy rains.

## Incubation

Usually 2 to 7 days, but sometimes can be longer.

## Period of Communicability

May extend for months in untreated people. Infectivity ceases within hours of appropriate antibiotic therapy. Patients should be isolated / excluded from school until 24 hours after treatment.

## Case Definition

Cases may be divided into confirmed or probable. Both confirmed and probable cases should be treated according to the recommendations below and notified to the local Centre for Disease Control (CDC)\*.

### Clinical features

A clinical illness usually characterised by intense inflammation of the conjunctivae, copious purulent discharge with or without periorbital oedema. Low grade, mild conjunctivitis lasting several weeks may also occur.

### Confirmed case

*Neisseria gonorrhoeae* detected in a conjunctival specimen by:

- Culture,

**OR**

- A nucleic acid technique (NAT) such as Polymerase Chain Reaction (PCR) where 2 different assays are both positive for the same specimen.

### Probable case

A clinically compatible illness **and either**:

- gram negative intracellular diplococci visible on microscopy of a conjunctival specimen,

**OR**

- epidemiologically linked to a laboratory confirmed case within 1 week of a confirmed case and occurring either in the same household or same schoolroom environment

\*Note: There is a distinction made between gonococcal conjunctivitis and ophthalmia neonatorum based on age (28 days) for notification purposes.

## Epidemic definition

At least 2 persons with a *confirmed* case occurring in separate households in the same community within 1 month of each other.

## Pathology tests

All suspect patients should have 2 swabs taken, 1 for microscopy, culture and sensitivity (MC&S) and 1 for PCR for gonorrhoea and chlamydia.

- For MC&S: roll the swab on a slide and let the slide air dry, place the swab in Modified Amies or Stuart's transport medium (do not refrigerate).
- For PCR place the swab in a dry tube and put in the fridge.

## Management of Cases

### *For all suspected cases*

- Collect swabs as above.
- Irrigate the eyes with saline solution to remove the discharge.
- If the eye is very crusted it may be necessary to bathe the eyes to remove the crusting. If so, use sterile cotton wool balls well moistened with normal saline. Wipe from inner canthus outwards. Use a fresh ball for each wipe and dispose of in a biohazard bag.
- **If possible check visual acuity, and check cornea for ulceration with fluorescein. If either are abnormal discuss with an ophthalmologist regarding management. Arrange immediate transfer to hospital if there is corneal ulceration.**
- If the eyelids are too swollen to be able to examine the eye, discuss with an ophthalmologist and consider immediate treatment and transfer to hospital.
- Antibiotic eye drops may be of some use in addition to parenteral antibiotics if there is corneal ulceration or staining.

See additional investigations and treatment as indicated below for babies, sporadic cases and epidemic situations.

### ***Management of Cases in babies***

Conjunctivitis in babies less than 6 weeks old may be due to neonatal infection with *N. gonorrhoea*, *Chlamydia trachomatis* or a range of other organisms. A test for gonorrhoea should be done in all babies of this age with conjunctivitis.

*For babies less than 2 weeks old, or with severe conjunctivitis or with corneal ulceration:*

- Do investigations and eye toilet as *for all suspected cases*.
- **Give 50mg/kg of IM ceftriaxone to a maximum of 125mg immediately.**

- Arrange immediate transfer to hospital for baby and mother.
- If diagnosis is confirmed, arrange full STI check and treatment for gonorrhoea for mother and her sexual partner(s).

*For babies 2-6 weeks old without severe conjunctivitis and no sign of corneal ulceration:*

- Do investigations and eye toilet as *for all suspected cases*.
- Consult with a paediatrician regarding management as hospitalisation may be needed (these babies may have or develop neonatally acquired chlamydia conjunctivitis or pneumonia).

### **Management of sporadic cases in older children or adults**

This may be diagnosed on initial clinical suspicion, but more usually will be less severe clinically and diagnosed on receipt of the test result.

- Do investigations and eye toilet as *for all suspected cases*.
- All persons (children and adults) with confirmed or likely gonococcal conjunctivitis should have either a low vaginal swab (either self administered or by the clinician), or first void urine test for MC&S and gonorrhoea and chlamydia PCR. Persons found to have genital infection should have a full STI work up and management as per standard practice.
- If there is no loss of visual acuity or corneal staining, treat with:

#### **Ceftriaxone 50mg/kg to a maximum of 1g as a single IM or IV dose**

- Exclude from school or child care for 24 hours after treatment.
- All members of the household, or members of same classroom for a school age child, should be examined for conjunctivitis. If signs are present, swabs should be taken as *for all suspected cases*.

Immediate treatment of household or school room contacts even if they have no symptoms may be necessary to prevent complications in them or further dissemination. Discuss with a senior Public Health Physician. Factors in favour of such treatment would be:

- remote location or difficulty of access to clinical care or oversight,
- crowded accommodation,
- sub-optimal understanding and personal practices of hygiene, or
- presence of children in the household.

### **Management of an Epidemic situation**

All members of the household where there is an affected person, and members of same classroom for a school age child, should be examined for conjunctivitis. If signs are present, swabs should be taken as *for all suspected cases*.

There is no need for genital or urine specimens in an epidemic situation.

All members of the household and members of same classroom for a school age child, should be treated regardless of whether there are clinical signs of conjunctivitis.

**Treat both children and adults:**

- Procaine penicillin intramuscularly (IM) as a single dose (50,000 units = 50 mg /kg (to a maximum of 1,500,000 units = 1.5g)

**Using Procaine Penicillin 1,500,000 units = 1.5g/3.4ml**

| Weight             | mg     | Amount |
|--------------------|--------|--------|
| 3 kg to < 6 kg     | 250 mg | 0.6 ml |
| 6 kg to < 10 kg    | 375 mg | 0.8 ml |
| 10 kg to < 15 kg   | 500 mg | 1.1 ml |
| 15 kg to < 20 kg   | 750 mg | 1.7 ml |
| 20 kg to < 30 kg   | 1.0 g  | 2.3 ml |
| Greater than 30 kg | 1.5 g  | 3.4 ml |

**OR**

**Amoxycillin plus probenecid as a single oral dose**

| Weight           | Amoxycillin | Probenecid |
|------------------|-------------|------------|
| 3 kg to < 6 kg   | 500 mg      | nil        |
| 6 kg to < 10 kg  | 1g          | nil        |
| 10 kg to < 15 kg | 1.5g        | 250 mg     |
| 15 kg to < 20 kg | 2g          | 500 mg     |
| 20 kg or over    | 3g          | 1g         |

For people with hypersensitivity to penicillin (excluding immediate hypersensitivity, i.e. anaphylactic reaction) or where the standard treatment has failed, or if infection is known to be due to penicillinase producing *Neisseria gonorrhoeae* (PPNG), treatment with ceftriaxone should be given as above. Failed treatment is defined as no substantial decrease in discharge, conjunctival injection or peri-orbital oedema within 24 hours of treatment.

The recommended treatment in an epidemic situation differs from sporadic cases for the following reasons:

- the potentially large numbers of people requiring treatment quickly and easier use of and access to procaine penicillin,
- cost effectiveness,
- to minimise widespread use of ceftriaxone to reduce selection pressure for resistant organisms, and

- the experience of effectiveness of the above regimes in 4 widespread epidemics in the past 20 years,

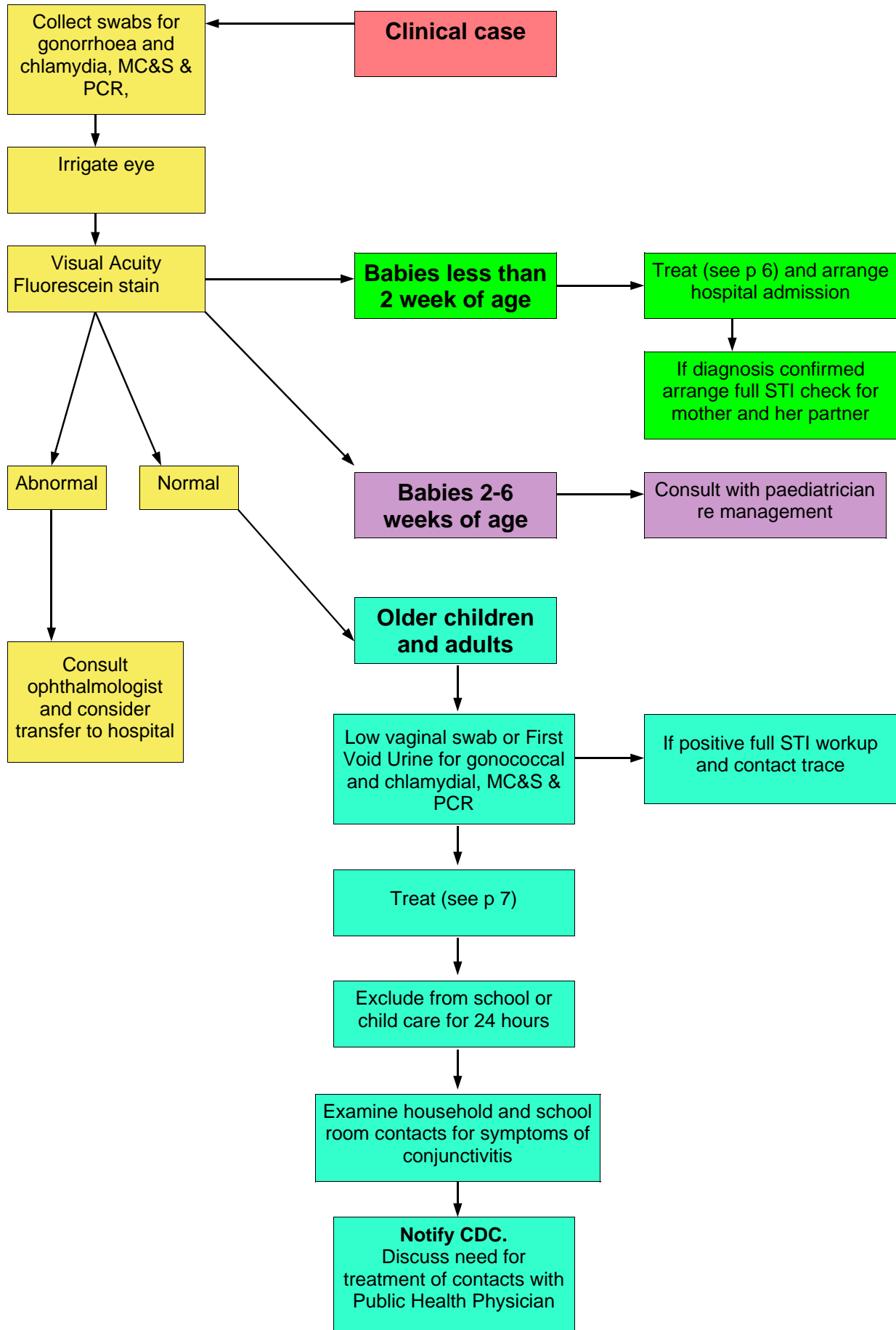
### **General measures and advice for all cases and contacts**

- Encourage frequent washing of face and hands with warm water and soap and using clean towels.
- Provide information to all close household contacts and family members on the importance of good hygiene as a way of preventing the spread of infection.
- Warn families to re-present if there is persisting eye infection, fevers or other symptoms such as arthritis.

## **Bibliography**

1. Alfonso E, Friedland B, Hupp S, Olsen K, Senikowich K, Sklar VE et al. *Neisseria gonorrhoeae* conjunctivitis. An outbreak during an epidemic of acute hemorrhagic conjunctivitis. *JAMA* 1983; 250(6):794-795.
2. Chandler JW. Ocular infections associated with sexually transmitted diseases and AIDS. In: KK Holmes et al, editor. *Sexually Transmitted Diseases*. 3rd ed. New York: McGraw-Hill; 1999.
3. Coats DK, Carothers TS, Brady-McCreery K, Paysse EA. Ocular infectious diseases. In: Feigin RD, Demmler GJ, Cherry JD, Kaplan SL, editors. *Textbook of pediatric infectious diseases*. 5th ed. New York: Saunders; 2004.
4. Gutman LT. Gonococcal infection. In: Remington JS, Klein JO, editors. *Infectious disease of the fetus and newborn infant*. 3rd ed. New York: WB Saunders; 2001.
5. Haimovici R, Roussel TJ. Treatment of gonococcal conjunctivitis with single-dose intramuscular ceftriaxone. *Am J Ophthalmol* 1989; 107(5):511-514.
6. Hansen T, Burns RP, Allen A. Gonorrhoeal conjunctivitis an old disease returned. *JAMA* 1966; 195(13):1156.
7. Hook EW, Handsfield HH. Gonococcal infections in the adult. In: KK Holmes et al, editor. *Sexually Transmitted Diseases*. 3rd ed. New York: McGraw-Hill; 1999. 451-466.
8. Hoosen AA, Kharsany AB, Ison CA. Single low-dose ceftriaxone for the treatment of gonococcal ophthalmia--implications for the national programme for the syndromic management of sexually transmitted diseases. *S Afr Med J* 2002; 92(3):238-240.
9. Isada CM, Meisler DM. Gonococcal ocular disease. In: Fraunfelder FT, Hampton Roy F, editors. *Current ocular therapy*. 3rd ed. New York: WB Saunders; 2000.
10. Kaye G, Ziskind A, Salmon JF. Gonococcal conjunctivitis. *S Afr Med J* 1989; 75(11):552.
11. Laga M, Naamara W, Brunham RC, D'Costa LJ, Nsanze H, Piot P et al. Single-dose therapy of gonococcal ophthalmia neonatorum with ceftriaxone. *N Engl J Med* 1986; 315(22):1382-1385.
12. Lepage P, Kestelyn P, Bogaerts J. Treatment of gonococcal conjunctivitis with a single intramuscular injection of cefotaxime. *J Antimicrob Chemother* 1990; 26 Suppl A:23-27.
13. Mak DB, Smith DW, Harnett GB, Plant AJ. A large outbreak of conjunctivitis caused by a single genotype of *Neisseria gonorrhoeae* distinct from those causing genital tract infections. *Epidemiol Infect* 2001; 126(3):373-378.
14. Matters R, Wong I, Mak D. An outbreak of non-sexually transmitted gonococcal conjunctivitis in Central Australia and the Kimberley region. *Commun Dis Intell* 1998; 22(4):52-56.
15. Matters R. Non-sexually transmitted gonococcal conjunctivitis. *Commun Dis Intell* 1981; 13:3.
16. McKeown DJ, Mears MP. Epidemic gonococcal conjunctivitis in Central Australia--a manifestation of cyclical weather patterns? *Med J Aust* 1998; 169(7):397.
17. Merianos A, Condon RJ, Tapsall JW, Jayathissa S, Mulvey G, Lane JM et al. Epidemic gonococcal conjunctivitis in central Australia. *Med J Aust* 1995; 162(4):178-181.
18. Mikru FS, Molla T, Ersumo M, Henriksen TH, Klungseyr P, Hudson PJ et al. Community-wide outbreak of *Neisseria gonorrhoeae* conjunctivitis in Konso district, North Omo administrative region. *Ethiop Med J* 1991; 29(1):27-35.
19. O'Farrell N, Blignaut P. Gonococcal conjunctivitis. *S Afr Med J* 1989; 76(10):580.
20. Rebenstein JB, Jick SL. Disorders of the conjunctiva and limbus. In: Yanoff M, Duker JS, editors. *Ophthalmology*. 2nd ed. St. Louis: Mosby Inc; 2005.
21. Sexually transmitted diseases treatment guidelines 2002. Centers for Disease Control and Prevention. *MMWR Recomm Rep* 2002; 51(RR-6):1-78.
22. Ullman S, Roussel TJ, Culbertson WW, Forster RK, Alfonso E, Mendelsohn AD et al. *Neisseria gonorrhoeae* keratoconjunctivitis. *Ophthalmology* 1987; 94(5):525-531.
23. Wan WL, Farkas GC, May WN, Robin JB. The clinical characteristics and course of adult gonococcal conjunctivitis. *Am J Ophthalmol* 1986; 102(5):575-583.
24. World Health Organization. Guidelines for the management of sexually transmitted infections. 2003. Geneva, World Health Organization.

## Management of gonococcal conjunctivitis



***For further information contact***

*Centre for Disease Control Darwin*

*Ph: 08 89228044*

*Fax: 08 89228310*

*[www.nt.gov.au/health/cdc](http://www.nt.gov.au/health/cdc)*

***OR***

***Your regional CDC***

*Alice Springs Ph: 08 89517549*

*Katherine Ph: 08 89739049*

*Nhulunbuy Ph 08 89870357*

*Tennant Creek Ph 08 89624250*